Minimally Invasive Options in Dupuytren's Contracture: Aponeurotomy, Enzymes, Stretching, and Fat Grafting

Amanda Murphy, M.D.
Donald H. Lalonde, M.D.
Charles Eaton, M.D.
Keith Denkler, M.D.
Steven E. R. Hovius, M.D., Ph.D.
Anthony A. Smith, M.D.
Alison Martin, M.D.
Atanu Biswas, M.D.
C. Van Nieuwenhoven, M.D., Ph.D.

Halifax, Nova Scotia, Canada

Learning Objectives: After studying this article, the participant should be able to: (1) Perform needle aponeurotomy, fat grafting, Digit Widget insertion, and collagenase injection for Dupuytren's cords. (2) Describe how cords can be stretched without surgery. (3) Explain to patients the risks and benefits of these new alternatives of treatments.

Summary: Surgery for Dupuytren's contracture used to be the only alternative of treatment. The past 5 years have seen the widespread adoption of minimally invasive treatments in the form of needle aponeurotomy and collagenase injection to disrupt the cords and restore range of motion. Even newer and perhaps as effective treatments such as fat grafting and mechanical stretching with the Digit Widget may also end up being important tools of treatment. The reader will be introduced to all of these modalities with text, illustration, and videos. (*Plast. Reconstr. Surg.* 134: 822e, 2014.)

NEEDLE APONEUROTOMY

Originally described as one of the first treatments for Dupuytren's contracture by Sir Henry Cline in 1777, aponeurotomy or fasciotomy was repopularized by French rheumatologists as percutaneous needle fasciotomy.[1] It is rapidly gaining popularity among hand surgeons and patients because of its minimal morbidity.

As described by Eaton, the four requirements for percutaneous needle aponeurotomy in management of Dupuytren's are contracture caused by a palpable cord beneath redundant skin in a cooperative patient.[2] It can be performed safely in an office setting under local anesthesia. Some place the local anesthetic in the skin only to decrease the possibility of digital nerve damage. The disadvantage is that patients can feel more discomfort than if the entire area is blocked with local anesthesia as performed by others.

To prevent skin tears, a plane between the dermis and the cord is developed by subcision. A needle (frequently 18- to 22-gauge) is introduced parallel to the skin to detach areas of adherence between the cord and the skin. Horizontal movement parallel to the skin clears away the vertical dermal attachments. (**See Video, Supplemental Digital Content 1**, which illustrates the percutaneous needle aponeurotomy of a left ring finger Dupuytren's cord with metacarpophalangeal and proximal interphalangeal joint contractures of 45 and 65 degrees, respectively. This video is available in the "Related Videos" section of the full-text article on PRSJournal.com or at ***http://links.lww.com/PRS/B101***.)

To weaken the cord, it can be perforated with up-and-down movements or sweeping side-to-side movement with a hypodermic needle perpendicular to the cord as demonstrated clearly in Videos 1 and 2. (**See Video, Supplemental Digital Content 1**, ***http://links.lww.com/PRS/B101***; **see Video, Supplemental Digital Content 2**, which illustrates the technique of extended needle aponeurotomy and lipofilling. The patient presented with a central

Disclosure: *The authors have no financial interest to declare in relation to the content of this article.*

Related Video content is available for this article. The videos can be found under the "Related Videos" section of the full-text article, or, for Ovid users, using the URL citations published in the article.

From Dalhousie University.
Received for publication July 3, 2013; accepted November 8, 2013.

DOI: 10.1097/PRS.0000000000000603

Video 1. Supplemental Digital Content 1 illustrates the percutaneous needle aponeurotomy of a left ring finger Dupuytren's cord with metacarpophalangeal and proximal interphalangeal joint contractures of 45 and 65 degrees, respectively. This video is available in the "Related Videos" section of the full-text article on PRSJournal.com or at ***http://links.lww.com/PRS/B101.***

Video 2. Supplemental Digital Content 2 illustrates the technique of extended needle aponeurotomy and lipofilling. The patient presented with a central cord to the third, fourth, and fifth digits with metacarpophalangeal joint contractures. This video is available in the "Related Videos" section of the full-text article on PRSJournal.com or available at ***http://links.lww.com/PRS/B102.***

cord to the third, fourth, and fifth digits with metacarpophalangeal joint contractures. This video is available in the "Related Videos" section of the full-text article on PRSJournal.com or at ***http://links.lww.com/PRS/B102.***) The metacarpophalangeal and proximal interphalangeal joints are then passively extended to rupture the cord.

It is recommended that patients rest and elevate the hand for 2 or 3 days to let internal wounds clot and swelling settle. Most patients are able to perform most activities with their operated hand within 1 week after the procedure.

In a prospective, randomized, controlled trial, van Rijssen et al. compared results of needle aponeurotomy with limited fasciectomy. They analyzed results of 115 hands with preoperative minimal passive extension deficit of greater than or equal to 30 degrees at 5 years after intervention (**Level of Evidence: Therapeutic, II**).[3] The authors had previously reported early data from this study indicating that needle aponeurotomy has significantly faster functional recovery time compared with limited fasciectomy. However, needle aponeurotomy is less effective than limited fasciectomy for moderately severe and severe (Tubiana stages III and IV) forms of Dupuytren's contracture.[4] The recurrence rate at 5 years, defined as a greater than or equal to 30-degree increase in total passive extension deficit, was 85 percent and 21 percent in the needle aponeurotomy and limited fasciectomy groups, respectively.

Does steroid injection help the results of needle aponeurotomy? In a recent Canadian[5] prospective, randomized, controlled trial, 47 patients received either needle aponeurotomy alone or needle aponeurotomy with triamcinolone acetonide injection to palpable areas of thickness at 6 weeks and 3 months after needle aponeurotomy (**Level of Evidence: Therapeutic, II**). The authors of that study report an 87 percent correction in total active extension deficit in the steroid group at 6 months compared with 64 percent in the needle aponeurotomy–alone group. However, the baseline total active extension deficit was 103 degrees in the needle aponeurotomy plus triamcinolone acetonide group and only 80 degrees in the needle aponeurotomy–alone group. The result of increase in the percentage of correction may have been in part attributable to greater potential for correction in the needle aponeurotomy plus triamcinolone acetonide group. The study was also limited by its short-term follow-up of 6 months. Although steroid injection may prove to be a promising adjunct to needle aponeurotomy, longer term studies with equivalent cohorts are needed.

Evidence-based comparison of outcomes between different procedures and variations of the same procedure remains difficult because of differences in reporting and lack of a universally agreed-on definition for recurrence.[6] Although it is widely accepted that recurrence rates increase with time, there is great variation in reported rates of contracture recurrence. A systematic review of recurrence rates demonstrated a range of 12 to 73 percent reported recurrence for limited fasciectomy and 33 to 100 percent for fasciotomy/aponeurotomy.[7]

By redefining the criteria for success and recurrence of limited fasciectomy versus needle

aponeurotomy to match the structure defined in collagenase publications,[8–10] van Rijssen et al.[3] (**Reference 9 Level of Evidence: Therapeutic, I**; **Reference 10 Level of Evidence: Therapeutic, II**) were able to directly compare outcomes for limited fasciectomy, needle aponeurotomy, and collagenase. Successful treatment was defined as correction of contracture to 5 degrees or less. In the management of metacarpophalangeal joint contractures, success was attained in 94 percent of patients treated with limited fasciectomy, 65 to 76 percent treated with collagenase, and 55 percent treated with needle aponeurotomy. Successful treatment of proximal interphalangeal joint contractures was 47 percent, 28 to 40 percent, and 26 percent for limited fasciectomy, needle aponeurotomy, and collagenase, respectively. Recurrence was defined as a greater than or equal to 20-degree loss in extension in joints initially corrected to less than or equal to 5 percent. For all joints, overall recurrence was 5 percent at 5 years for limited fasciectomy, 22 percent at 5 years for needle aponeurotomy, and 19 percent at 2 years for collagenase. A recent systematic review by Chung revealed that needle aponeurotomy has a significantly higher recurrence rate than open partial fasciectomy, and partial open fasciectomy has a significantly higher recurrence rate than collagenase injection.[39]

NEEDLE APONEUROTOMY AND FAT GRAFTING

Hovius et al. describe their results of combining extensive percutaneous release with a novel concept of fat grafting in a cohort of 50 patients (**Level of Evidence: Therapeutic, IV**).[11] (For a film on fat grafting technique, **see Video, Supplemental Digital Content 2**, ***http://links.lww.com/PRS/B102***.) The percutaneous release was performed under regional or general anesthesia. This was followed by up to 10 ml per ray of abdominal or flank fat graft injected subcutaneously into the palm and digit along the tracks of the ruptured cords. At 44-week follow-up, the authors report a mean correction of proximal interphalangeal joint contracture from 61 degrees to 27 degrees, and mean correction of metacarpophalangeal joint contracture from 37 degrees to −5 degrees. The authors report subjective observation of fat survival, which is both palpable and visible between the skin and the released cords (Figs. 1 and 2). They theorize that fat grafts help to decrease adhesions and separate strands of cord scar in the hand, as it has irradiated beds in breast reconstruction patients.[12] The authors are currently working on a prospective, multicenter, randomized, controlled trial in Rotterdam to compare this new method with standard limited fasciectomy; early results are promising.

COLLAGENASE

Suggested medical interventions for treatment of Dupuytren's contracture have included colchicine,[13] allopurinol,[14] steroids,[15] prostaglandins, and calcium channel blockers,[16] but the only agent to demonstrate sustained clinical efficacy in prospective randomized trials to date is clostridial collagenase.[17] Research has established proliferation of myofibroblasts as the pathologic entity in Dupuytren's contracture.[18,19] The result is a pathologic increase in type III collagen, which is normally absent in adult palmar fascia.[20] *Clostridium histolyticum* collagenases are metalloproteases that lyse the three-dimensional structure of collagen.

In 2010, the U.S. Food and Drug Administration granted American approval for clinical use of injectable collagenase *C. histolyticum* marketed under the name Xiaflex (Auxilium Pharmaceuticals, Inc., Malvern, Pa.). It became available in Canada in April of 2013. Xiaflex is a purified

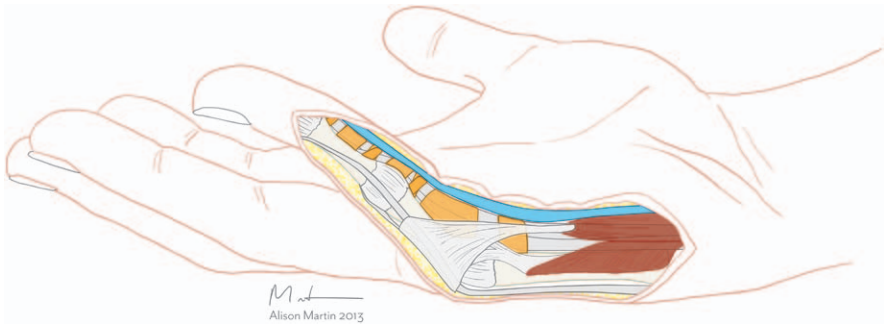

Fig. 1. Illustration of a Dupuytren's cord in the fifth digit with associated metacarpophalangeal joint contracture. Note the adherence of overlying skin to the diseased fascia.

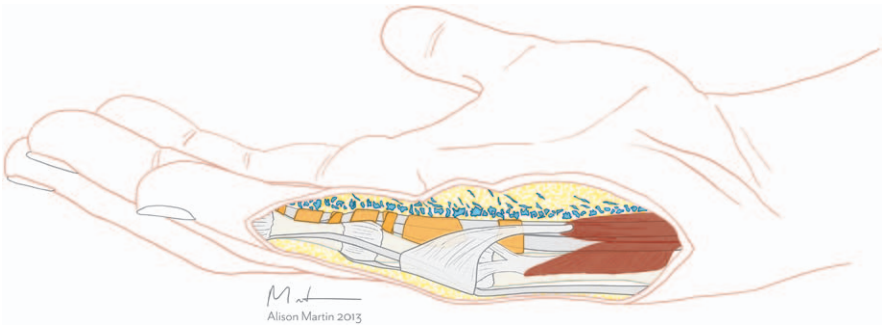

Fig. 2. Illustration of the same cord following extensive percutaneous aponeurotomy and fat grafting. Note the presence of fat cells between the perforated cord and between the cord and skin.

mixture of two collagenases (AUX-I and AUX-II) from *C. histolyticum* that preferentially cleaves fibrillar collagens types I and III,[21–26] characteristic of Dupuytren's cords, while leaving globular collagens (types IV and VI), that comprise vessel basement membranes and perineurium, intact.[27,28] Xiaflex is approved for treatment of adult patients with Dupuytren's contracture and a palpable cord. According to the manufacturer's guidelines, 0.58 mg of Xiaflex is injected directly into one section of the cord in three aliquots. The patient returns 24 hours later to have the cord ruptured by manually extending the finger. Injections and finger extension procedures may be administered up to three times per cord at 4-week intervals. Only one cord may be injected at a time.

To date, clinical efficacy and safety of Dupuytren's treatment with *C. histolyticum* collagenase has been demonstrated in two double-blind, placebo-controlled studies, the Collagenase Option for Reduction of Dupuytren's I and II trials,[9,10] and several observational studies.[26,29–31] In the Collagenase Option for Reduction of Dupuytren's I trial (n = 3080), 64 percent of *C. histolyticum* collagenase–injected cords met the defined endpoint of contracture reduction to within 0 to 5 degrees of full extension within 30 days of the last injection compared with 7 percent of placebo-injected cords ($p < 0.001$).[9] Similar results were reported in the Collagenase Option for Reduction of Dupuytren's II trial (n = 66), with 44 percent of *C. histolyticum* collagenases–injected cords achieving the primary endpoint versus 5 percent for placebo ($p < 0.001$).[10] Most recently, two concurrent open-label studies, JOINT I (United States) and JOINT II (Australia and Europe), published short-term data of *C. histolyticum* collagenase injections for treatment of Dupuytren's contracture in 587 patients (**Therapeutic, Level IV Evidence**).[32] Patients with fixed-flexion contractures of metacarpophalangeal (20 to 100 degrees) or proximal interphalangeal (20 to 80 degrees) joints received up to three injections per cord (mean, 1.4 ± 0.7 injections). Follow-up was at 1, 2, 6, and 9 months. Clinical success was defined as contracture reduction to within 0 to 5 degrees of full extension at 30 days after final injection. The success rate was 70 percent in treated metacarpophalangeal joints and 37 percent in proximal interphalangeal joints. Individuals with less severe contractures at baseline (≤50 degrees) had better response to treatment. The authors report that 97 percent of patients had at least one adverse event related to treatment; however, most were localized to the injection site and resolved without intervention (e.g., swelling, bruising, lymphadenopathy). These results are consistent with previous studies.[9,26,29,30] The Collagenase Option for Reduction of Dupuytren's II trial (n = 66) reported serious complications (e.g., pulley rupture, disease aggravation, nerve injury) requiring additional treatment of 2.2 percent in patients treated with collagenase.[10]

As a follow-up to the Collagenase Option for Reduction of Dupuytren's I and II trials, the long-term safety and efficacy of collagenase is currently being examined in a prospective, 5-year study: the Collagenase Option for Reduction of Dupuytren's Long-Term Evaluation of Safety Study (**Level of Evidence: Therapeutic, IV**).[33] The authors enrolled 1080 *C. histolyticum* collagenase–treated joints from five previous studies. The primary endpoint was recurrence in a previously successfully treated joint, defined as 20 degrees or greater worsening in contracture or medical/surgical intervention to correct worsening contracture. The recently published 3-year data reported an overall recurrence of 35 percent. Of these, 7 percent had an intervention performed. No new long-term or serious adverse events attributed to *C. histolyticum* collagenase were identified.

Of 1082 patients treated, the authors report three flexor tendon ruptures (0.3 percent) and one pulley injury (0.1 percent).

Auxilium Pharmaceuticals, Inc., marketer of the commercially available form of *C. histolyticum* collagenase, Xiaflex, recently released the 30-month safety update after U.S. Food and Drug Administration approval. In over 27,000 injections, a total of 19 flexor tendon ruptures (0.09 percent) and three ligament injuries (0.01 percent) from approximately 21,000 patients were reported. In addition, there has been a single report of complex regional pain syndrome (0.005 percent) that resolved within 3 months and a single case of residual neurapraxia (0.005 percent).[34]

Recently, there has been a relative abundance of publications on the use of collagenase and needle aponeurotomy as minimally invasive options for the treatment of Dupuytren's contracture; however, a direct comparison is lacking in the literature. Our authors, with multimodal experience, are discovering that enzyme treatments are helpful for patients who would like to avoid surgery. Surgeons who perform needle aponeurotomy or fasciectomy for Dupuytren's may use collagenase as a second step to dissolve recurrences or failures. The enzyme can also be useful for thick cords over the nerve, where needle aponeurotomy may present concerns. Needle aponeurotomy can be useful for patients who do not wish the prolonged recovery time from surgery, and who cannot afford collagenase injection.

The relative costs of the different treatments for Dupuytren's were recently analyzed by Chung and colleagues (Level II Economic and Decision Analysis).[40] They calculated that the cost of open partial fasciectomy was $820,114 per quality-adjusted life-year (QALY) gained over no treatment. The cost of needle aponeurotomy was $96,474 per QALY gained compared with no treatment. When they performed a sensitivity analysis and set the success rate at 100 percent, the cost of needle aponeurotomy was $49,631. When needle aponeurotomy was performed without surgical center or anesthesia costs and with reduced hand therapy, the cost was $36,570. When a complete collagenase injection series was priced at $250, the cost was $31,856 per QALY gained. When the injection series was priced at $945, the cost was $49,995 per QALY gained. At the market price of $5400 per injection, the cost was $166,268 per QALY gained. They concluded that (1) open partial fasciectomy is not cost-effective, (2) needle aponeurotomy is cost-effective if the success rate is high, and (3) collagenase injection is cost-effective when priced under $945.

The complication profile for collagenase is very favorable. The dreaded tendon rupture can occur, but also occurs with needle aponeurotomy. The dreaded complications of fasciectomy include amputation or chronic pain syndromes, which are rare after needle or collagenase.

Methods to use the collagenase tool will change as more experience is gained. The following are 10 tips to improved collagenase use learned in over 400 injections performed by the first author (K.D.). Several can be seen in Video 3. (**See Video, Supplemental Digital Content 3**, which illustrates the technique used for Denkler collagenase injection for release of a fifth digit Dupuytren's cord with metacarpophalangeal joint contracture. The patient returns between 2 and 14 days after injection for manipulation and rupture of the cord. This video is available in the "Related Videos" section of the full-text article on PRSJournal.com or at ***http://links.lww.com/PRS/B103***.) Some of the material described below and in the video on collagenase is off-label use of the product, which the authors feel is an improvement:

1. Use the whole vial. To achieve this, pry off the vial top, bend the needle approximately 45 degrees, then tip the reconstituted enzyme container to remove all of the fluid.
2. The extra enzyme may be used more proximally, on a different ray, on the other hand, or to presoften a digit that is scarred after a previous fasciectomy.
3. Spreading out the enzyme helps avoid overconcentration on one area causing deeper penetration of the enzyme near the tendon or pulleys. The safety of the drug is more superficial and it should be used in the middle to the top of the cord. Careful, slow injection is helpful to prevent the enzyme from spilling into the subcutaneous tissues, where it is quickly metabolized by human proteases.
4. Manipulation may be better performed 2 to 14 days after injection. The delay may allow for better control of skin splits as the swelling resolves. Delayed manipulation also allows for proximal needle aponeurotomy at the time of the manipulation.
5. Routine use of local anesthesia for manipulation; use lidocaine with epinephrine blocks to reduce bruising.
6. Know your dosing. The entire vile contains 0.9 mg of collagenase. Metacarpophalangeal

Video 3. Supplemental Digital Content 3 illustrates the technique used for Denkler collagenase injection for release of a fifth digit Dupuytren's cord with metacarpophalangeal joint contracture. The patient returns between 2 and 14 days after injection for manipulation and rupture of the cord. This video is available in the "Related Videos" section of the full-text article on PRSJournal.com or at ***http://links.lww.com/PRS/B103.***

Video 4. Supplemental Digital Content 4 illustrates the operative technique and postoperative protocol of the Digit Widget device to treat proximal interphalangeal joint flexion contracture. This external fixator uses elastic soft-tissue traction to passively extend joint contractures associated with Dupuytren's disease. This video is available in the "Related Videos" section of the full-text article on PRSJournal.com or at ***http://links.lww.com/PRS/B104.***

joint dilution is 2.3 mg/ml. Each 0.1 cc on the syringe is 0.23 mg. For proximal interphalangeal joint dilution, the dose is 2.9 mg/ml or 0.29 mg of collagenase per 0.1 cc. Therefore, know your increments of 0.1 cc and 0.05 cc. Mixing 0.45 cc diluent per vial makes 2.0 mg/ml or 0.2 mg per 0.1-cc dose. Use 0.2-mg or 0.1-mg doses of collagenase as needed.

7. Use the enzyme like a chemical needle aponeurotomy.
8. Consider local injection "load." Too much enzyme in one area risks dissolving deeply. There is safety in spreading out the injection, as one can always come back later to administer another treatment.
9. Proximal needle aponeurotomy, or superficial subcision, may be performed at delayed manipulation while the ray is numb.
10. Try to avoid skin tears by observing manipulation so that blisters do not rupture.

STRETCHING

There is a widely held belief that stretching or ripping a Dupuytren's cord may make it worse. It also used to be believed that stretching could not lengthen the cords and lessen contracture in Dupuytren's disease. The Digit Widget (Hand Biomechanics Lab, Inc., Sacramento, Calif.) has clearly proven this to be a false assumption,[35] at least on a short-term follow-up basis. This is an external fixator device that applies elastic soft-tissue traction on the protruding screws on the dorsum of the phalanges, lengthening the soft tissues and neurovascular bundle gradually while decreasing the flexion contracture.

In the past 5 years, many surgeons have used the Digit Widget's elastic forces to passively extend longstanding proximal interphalangeal and metacarpophalangeal joint contractures caused by Dupuytren's disease. Some use it before surgery, whereas others use it after surgery. Literature on the Digit Widget is in its infancy, and the best way to use the device is still being discovered. (**See Video, Supplemental Digital Content 4**, which illustrates the operative technique and postoperative protocol of the Digit Widget device to treat proximal interphalangeal joint flexion contracture. This external fixator uses elastic soft-tissue traction to passively extend joint contractures associated with Dupuytren's disease. This video is available in the "Related Videos" section of the full-text article on PRSJournal.com or at ***http://links.lww.com/PRS/B104***.)

The best evidence is a Level III study that compared the results of fasciectomy and simultaneous proximal interphalangeal joint checkrein ligament release with Digit Widget soft-tissue distraction with or without operative joint release (**Therapeutic, Level III Evidence**).[36] The authors report greater improvement in extension in the Digit Widget group (mean improvement, 54.7 degrees) compared with those treated with fasciectomy and checkrein release (mean, 27.7 degrees). Of the 17 joints treated with the Digit Widget, three had complete correction of contracture and did not require surgical release. In addition, 15 percent

Video 5. Supplemental Digital Content 5 illustrates the operative technique of checkrein ligament release to treat proximal interphalangeal joint contractures in a cadaver model. Checkrein ligament release was traditionally the criterion standard in operative management of severe proximal interphalangeal joint contractures in Dupuytren's. This has largely been replaced by application of the Digit Widget as the treatment of choice in the senior author's practice. This video is available in the "Related Videos" section of the full-text article on PRSJournal.com or at ***http://links.lww.com/PRS/B105.***

of patients treated only with surgery actually experienced worsening contracture postoperatively, whereas all patients treated with the Digit Widget improved to some degree and did not experience any loss of extension over the 18-month follow-up. The authors' preferred technique of checkrein ligament release is demonstrated in Video 5. (**See Video, Supplemental Digital Content 5**, which illustrates the operative technique of checkrein ligament release to treat proximal interphalangeal joint contractures in a cadaver model. Checkrein ligament release was traditionally the criterion standard in operative management of severe proximal interphalangeal joint contractures in Dupuytren's. This has largely been replaced by application of the Digit Widget as the treatment of choice in the senior author's (A.S.) practice. This video is available in the "Related Videos" section of the full-text article on PRSJournal.com or at ***http://links.lww.com/PRS/B105***.) Although these results are promising, long-term data are required. At present, it is not clear whether stretching leads to durable correction.

Another recent example of success with stretching is a published series of patients in whom joint contractures were decreased with only progressive low-load night splinting and massage over a 12-month period.[37] There has also been some success in treating Dupuytren's palmar adhesions to the cords with massage.[38] However, both of these studies lack sufficient numbers to draw clinically applicable conclusions at present.

COMBINATION THERAPY

It seems likely that combinations of surgery, needle aponeurotomy, collagenase, stretching, and fat grafting will be the future in Dupuytren's contracture. Much work needs to be performed to determine where the pendulum will settle in discovering the best indications and combinations of these treatment modalities.

Because Dupuytren's contracture is not curable, starting with less invasive procedures such as needle aponeurotomy or collagenase can be a reasonable approach, as they have a much shorter recovery time than surgery, even though the time to recurrence may be less than with surgery. Collagenase may have a longer lasting effect than needle aponeurotomy and may be a better choice for those who can afford it. Fasciectomy can be reserved for more severe or recurrent disease not amenable to these lesser first-step treatments, but it has more complications and the recovery time is longer. In addition, the scarring from surgery and the fat loss is long lasting. Fat grafting has potential in Dupuytren's fingers, as it has been found to be useful in irradiated breast reconstruction. Stretching with the Digit Widget or with therapy may also find its place in the treatment of this disease.

Amanda Murphy, M.D.
Division of Plastic & Reconstructive Surgery
QEII HSC - HI Site
4447 1796 Summer St
Halifax, Nova Scotia, Canada
B3H 3A7
amurphy.dal@gmail.com

REFERENCES

1. Lermusiaux JL, Debeyre N. Le traitement medical de la maladie de Dupuytren. In: de Seze S, Ryckewaert A, Kahn MF, Guerin CI, eds. *L'actualite rhumatologique 1979.* Paris: Expansion Scientifique Francaise; 1980:338–343.
2. Eaton C. Percutaneous fasciotomy for Dupuytren's contracture. *J Hand Surg Am.* 2011;36:910–915.
3. van Rijssen AL, ter Linden H, Werker PM. Five-year results of a randomized clinical trial on treatment in Dupuytren's disease: Percutaneous needle fasciotomy versus limited fasciectomy. *Plast Reconstr Surg.* 2012;129:469–477.
4. van Rijssen AL, Gerbrandy FS, Ter Linden H, Klip H, Werker PM. A comparison of the direct outcomes of percutaneous needle fasciotomy and limited fasciectomy for Dupuytren's disease: A 6-week follow-up study. *J Hand Surg Am.* 2006;31:717–725.
5. McMillan C, Binhammer P. Steroid injection and needle aponeurotomy for Dupuytren contracture: A randomized, controlled study. *J Hand Surg Am.* 2012;37:1307–1312.
6. Kan HJ, Verrijp FW, Huisstede BM, Hovius SE, van Nieuwenhoven CA, Selles RW. The consequences of different definitions for recurrence of Dupuytren's disease. *J Plast Reconstr Aesthet Surg.* 2013;66:95–103.

7. Werker PM, Pess GM, van Rijssen AL, Denkler K. Correction of contracture and recurrence rates of Dupuytren contracture following invasive treatment: The importance of clear definitions. *J Hand Surg Am.* 2012;37:2095–2105.e7.
8. Larocerie-Salgado J, Davidson J. Nonoperative treatment of PIPJ flexion contractures associated with Dupuytren's disease. *J Hand Surg Eur Vol.* 2012;37:722–727.
9. Hurst LC, Badalamente MA, Hentz VR, et al.; CORD I Study Group. Injectable collagenase *C. histolyticum* for Dupuytren's contracture. *N Engl J Med.* 2009;361:968–979.
10. Gilpin D, Coleman S, Hall S, Houston A, Karrasch J, Jones N. Injectable collagenase *C. histolyticum*: A new nonsurgical treatment for Dupuytren's disease. *J Hand Surg Am.* 2010;35:2027–2038.e1.
11. Hovius SE, Kan HJ, Smit X, Selles RW, Cardoso E, Khouri RK. Extensive percutaneous aponeurotomy and lipografting: A new treatment for Dupuytren disease. *Plast Reconstr Surg.* 2011;128:221–228.
12. Schultz I, Lindegren A, Wickman M. Improved shape and consistency after lipofilling of the breast: Patients' evaluation of the outcome. *J Plast Surg Hand Surg.* 2012;46:85–90.
13. Dominguez-Malagon HR, Alfeiran-Ruiz A, Chavarria-Xicotencatl P, Duran-Hernandez MS. Clinical and cellular effects of colchicine in fibromatosis. *Cancer* 1992;69:2478–2483.
14. Murrell GA, Francis MJ, Bromley L. Free radicals and Dupuytren's contracture. *BMJ (Clin Res Ed.)* 1987;295: 1373–1375.
15. Ketchum LD, Donahue TK. The injection of nodules of Dupuytren's disease with triamcinolone acetonide. *J Hand Surg Am.* 2000;25:1157–1162.
16. Rayan GM, Parizi M, Tomasek JJ. Pharmacologic regulation of Dupuytren's fibroblast contraction in vitro. *J Hand Surg Am.* 1996;21:1065–1070.
17. Badalamente MA, Hurst LC. Efficacy and safety of injectable mixed collagenase subtypes in the treatment of Dupuytren's contracture. *J Hand Surg Am.* 2007;32:767–774.
18. Chiu HF, McFarlane RM. Pathogenesis of Dupuytren's contracture: A correlative clinical-pathological study. *J Hand Surg Am.* 1978;3:1–10.
19. Luck JV. Dupuytren's contracture: A new concept of the pathogenesis correlated with surgical management. *J Bone Joint Surg Am.* 1959;41:635–664.
20. Brickley-Parsons D, Glimcher MJ, Smith RJ, Albin R,Adams JP. Biochemical changes in the collagen of the palmar fascia in patients with Dupuytren's disease. *J Bone Joint Surg Am.* 1981;63:787–797.
21. Mookhtiar KA, Van Wart HE. *C. histolyticum* collagenases: A new look at some old enzymes. *Matrix Suppl.* 1992;1:116–126.
22. Matsushita O, Okabe A. Clostridial hydrolytic enzymes degrading extracellular components. *Toxicon* 2001;39:1769–1780.
23. Mallya SK, Mookhtiar KA, Van Wart HE. Kinetics of hydrolysis of type I, II, and III collagens by the class I and II *C. histolyticum* collagenases. *J Protein Chem.* 1992;11:99–107.
24. French MF, Bhown A, Van Wart HE. Identification of *C. histolyticum* collagenase hyperreactive sites in type I, II, and III collagens: Lack of correlation with local triple helical stability. *J Protein Chem.* 1992;11:83–97.
25. Van Wart HE, Steinbrink DR. Complementary substrate specificities of class I and class II collagenases from *C. histolyticum. Biochemistry* 1985;24:6520–6526.
26. Badalamente MA, Hurst LC. Efficacy and safety of injectable mixed collagenase subtypes in the treatment of Dupuytren's contracture. *J Hand Surg Am.* 2007;32:767–774.
27. Miyoshi S, Nakazawa H, Kawata K, Tomochika K, Tobe K, Shinoda S. Characterization of the hemorrhagic reaction caused by *Vibrio vulnificus* metalloprotease, a member of the thermolysin family. *Infect Immun.* 1998;66:4851–4855.
28. Trüeb B, Bornstein P. Characterization of the precursor form of type VI collagen. *J Biol Chem.* 1984;259:8597–8604.
29. Badalamente MA, Hurst LC. Enzyme injection as nonsurgical treatment of Dupuytren's disease. *J Hand Surg Am.* 2000;25:629–636.
30. Badalamente MA, Hurst LC, Hentz VR. Collagen as a clinical target: Nonoperative treatment of Dupuytren's disease. *J Hand Surg Am.* 2002;27:788–798.
31. Watt AJ, Curtin CM, Hentz VR. Collagenase injection as nonsurgical treatment of Dupuytren's disease: 8-year follow-up. *J Hand Surg Am.* 2010;35:534–539, 539.e1.
32. Witthaut J, Jones G, Skrepnik N, Kushner H, Houston A, Lindau TR. Efficacy and safety of collagenase *Clostridium histolyticum* injection for Dupuytren contracture: Short-term results from 2 open-label studies. *J Hand Surg Am.* 2013;38:2–11.
33. Peimer CA, Blazar P, Coleman S, et al. Dupuytren contracture recurrence following treatment with collagenase *C. histolyticum* (CORDLESS study): 3-year data. *J Hand Surg Am.* 2013;38:12–22.
34. Auxilium Pharmaceuticals, Inc. Auxilium Pharmaceuticals, Inc. announces 30 month Xiaflex safety update. Available at: http://ir.auxilium.com/phoenix.zhtml?c=142125&p=irol-news. Accessed April 12, 2012.
35. Agee JM, Goss BC. The use of skeletal extension torque in reversing Dupuytren contractures of the proximal interphalangeal joint. *J Hand Surg Am.* 2012;37:1467–1474.
36. Craft RO, Smith AA, Coakley B, Casey WJ III, Rebecca AM, Duncan SF. Checkrein ligament release after fasciectomy in the treatment of Dupuytren proximal interphalangeal joint contractures. *Plast Reconstr Surg.* 2011;128: 1107–1113.
37. Larocerie-Salgado J, Davidson J. Nonoperative treatment of PIPJ flexion contractures associated with Dupuytren's disease. *J Hand Surg Eur Vol.* 2012;37:722–727.
38. Christie WS, Puhl AA, Lucaciu OC. Cross-frictional therapy and stretching for the treatment of palmar adhesions due to Dupuytren's contracture: A prospective case study. *Man Ther.* 2012;17:479–482.
39. Chen N, Srinivasan R, Shauver M, Chung KC. A systematic review of outcomes of fasciotomy, aponeurotomy, and collagenase treatments for Dupuytren's contracture. *Hand.* 2011;6:250–255.
40. Chen N, Shauver M, Chung KC. Cost-effectiveness of open partial fasciectomy, needle aponeurotomy, and collagenase injection for Dupuytren contracture. *J Hand Surg Am.* 2001;36:1826–1834.